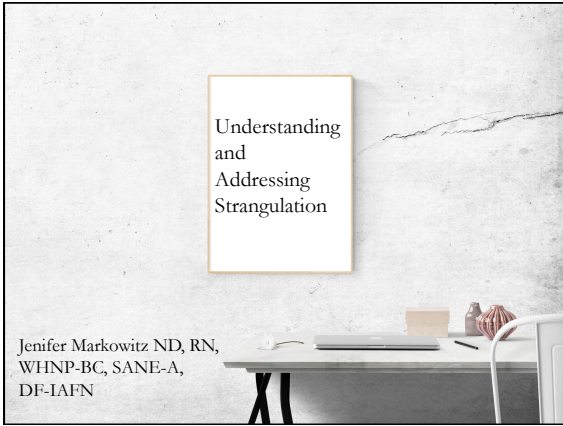

---

---

---

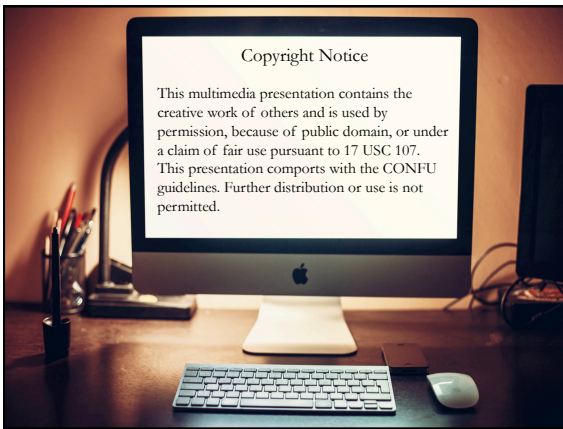
---

---

---

---

---



---

---

---

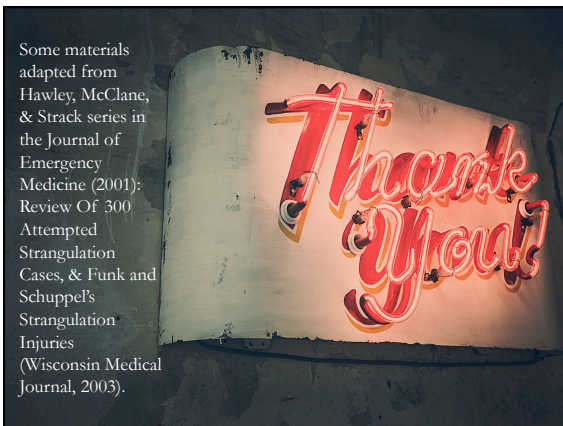
---

---

---

---

---



---

---

---

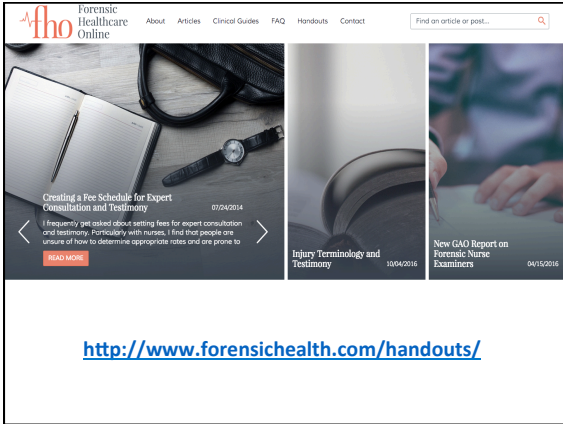
---

---

---

---

---




---

---

---

---

---

---

---

---

---

---

---

---

Forensic Healthcare Online

## Definition

- Strangulation is a form of asphyxia characterized by closure of the blood vessels and air passages of the neck as a result of external pressure on the neck
  - Differentiate from “choke” which means to have the trachea blocked partly or entirely by a foreign object (i.e. food)

(Anscombe, A.M., Knight, B.H. 1996)

---

---

---

---

---

---

---

---

---

---

---

---

Forensic Healthcare Online

## Asphyxia

Pathological changes caused by lack of oxygen, resulting in a deficiency of oxygen in the blood (hypoxia) and an increase in carbon dioxide in the blood and tissues

---

---

---

---

---

---

---

---

---

---

---

---

Forensic Healthcare Online

## Classification of Asphyxia

<b>Suffocation</b>
• Smothering
• Choking
• Confined space entrapment
<b>Strangulation</b>
• Manual
• Ligature
• Hanging
<b>Mechanical</b>
• Positional
• Compressive or traumatic
<b>Drowning</b>
• Death due to immersion in liquid

---

---

---

---

---

---

---

---

Forensic Healthcare Online

## Types of Strangulation

- Manual (most common)
  - Chokehold
- Ligature
- Hanging

---

---

---

---

---

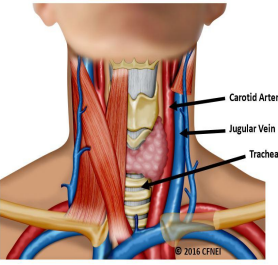
---

---

---

Forensic Healthcare Online

## Anatomy of the Neck



- Spinal Cord
- Airway
- Vascular supply to the brain

Carotid Artery  
Jugular Vein  
Trachea

© 2016 CPNET

---

---

---

---

---

---

---

---

Forensic Healthcare Online

### Vessel Occlusion

<b>Carotid artery occlusion</b> <ul style="list-style-type: none"><li>• Anterior neck</li><li>• 11 lbs of pressure for 10-15 seconds</li></ul>	<b>Jugular vein occlusion</b> <ul style="list-style-type: none"><li>• Lateral neck</li><li>• 4.4 lbs of pressure for 10-15 seconds</li></ul>
------------------------------------------------------------------------------------------------------------------------------------------------	----------------------------------------------------------------------------------------------------------------------------------------------

↕

UNCONSCIOUSNESS

---

---

---

---

---

---


---

---

Forensic Healthcare Online

### Airway Occlusion

- Usually minor (if any) role in causing death (as opposed to fracture of the trachea)
- 33 lbs of pressure to completely occlude
- At least 33 lbs of pressure or more to fracture tracheal cartilage



---

---

---

---

---

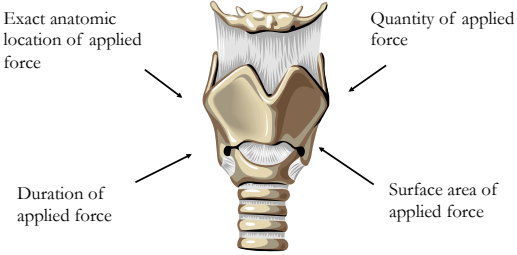
---

---

---

Forensic Healthcare Online

### Variables Required for Effective Strangulation



Exact anatomic location of applied force

Quantity of applied force

Duration of applied force

Surface area of applied force

Adapted from D. Hawley MD: Death by Strangulation

---

---

---


---

---

---

---

---

 Forensic Healthcare Online

## Fatality

Although death can occur at the time of strangulation, there is also potential for delayed fatalities days after the event.

---

---


---

---

---

---

---

 Forensic Healthcare Online

## Research

- Limited due to study constraints
- Much of the descriptive statistics we have regarding clinical picture is old

---

---


---

---

---

---

---

 Forensic Healthcare Online

## Statistics

- Range from 23-68% of DV/IPV victims (Wilbur, 2001).
- New study on strangulation and sexual assault found that >22% women assaulted by an intimate partner experienced strangulation compared to 6% of women with other assailants (Zilkens, et al., 2016).

---

---

---

---

---

---

---

Forensic Healthcare Online

### Strangulation in Children

- Research with children is limited, even though children can be presumed at greater risk of life-threatening injuries if strangled due to the variation in anatomy and physiology compared to adults.
- A child's airway is smaller and therefore easier to occlude than an adult. Relatively minor changes such as neck flexion or swelling can completely occlude a child's airway (Adewale, L., 2009).

---

---

---

---

---

---

---

---

Forensic Healthcare Online

### Strangulation in Children

- Muscle & ligament development in the neck is significantly less than that of adults with a larger head proportion (Jain et al., 2009).
- Cervical spine of a child more prone to injury and flexes at a higher level than the adult and there is an increased risk of spinal cord injury (Adewale, L., 2009).
- Cognitive and developmental differences may make it difficult for a child to effectively describe the strangulation event. (Baldwin-Johnson, C., Wiese, T., 2015).

[http://cymcdn.com/sites/www.forensicnurses.org/resource/resmgr/education/Strangulation\\_Position\\_Paper.pdf](http://cymcdn.com/sites/www.forensicnurses.org/resource/resmgr/education/Strangulation_Position_Paper.pdf)

---

---

---

---

---

---

---

---

Forensic Healthcare Online

### Clinical Presentation

---

---

---

---

---

---

---

---

Forensic Healthcare Online

### Signs and Symptoms

Dependent upon the method used, the force used, and the duration of the strangulation

---

---

---

---

---

---

---

Forensic Healthcare Online

### Signs and Symptoms

These can be minimal at first, since it takes time for underlying injury such as swelling and bleeding to cause issues

---

---

---

---

---

---

---

Forensic Healthcare Online

*We had a strangulation patient with a vertebral artery dissection from C6 to C2. She is in the ICU, no deficits, she came in the day after it happened only because she had so much neck pain and couldn't swallow.....NO external injuries noted....*

[Vertebral artery dissection = flap-like tear of the inner lining of the vertebral artery, which is located in the neck and supplies blood to the brain.]

---

---


---

---

---

---

---

 Forensic Healthcare Online

### Voice Changes

- May occur in up to 50% of patients
- Ranging from hoarseness to complete loss of voice

---

---


---

---

---

---

---

 Forensic Healthcare Online

### Swallowing Changes

- May be difficult, but not painful (dysphagia), or painful (odynophagia)
- May not be reported in immediate aftermath, but commonly reported in the weeks after the event.

---

---


---

---

---

---

---

 Forensic Healthcare Online

### Neck Swelling

- Edema from:
  - Internal hemorrhage
  - Injury of underlying neck structures
  - Fracture of the larynx causing subcutaneous emphysema

---

---

---

---

---

---

---

Forensic Healthcare Online

### Breathing Changes

- From hyperventilation or secondary to underlying neck and airway injury
- Difficulty breathing (including positional difficulties)
- Although changes may appear mild, they can become fatal within 36-72 hours

---

---

---

---

---

---

---

Forensic Healthcare Online

### Lung Injury

- Aspirating vomit during strangulation event can lead to *aspiration pneumonia*, an acute lung injury from inhaling gastric contents

---

---

---

---

---

---

---

Forensic Healthcare Online

### Neck Pain

- Decreased range of motion
- Localized or diffuse

---

---


---

---

---

---

---

 Forensic Healthcare Online

### Mental Status Changes

- Restlessness and combativeness secondary to hypoxia and severe stress reaction
- Changes can also be long-term, resulting in amnesia and psychosis

---

---


---

---

---

---

---

 Forensic Healthcare Online

### Visible Injury

It is no coincidence that the best medical evidence of strangulation is derived from post mortem examination (autopsy) of the body, but even in living survivors of strangulation assaults it may be possible to recognize a pattern of injury distinctive for strangulation.

-Dean Hawley, MD

---

---


---

---

---

---

---

 Forensic Healthcare Online

### Visible Injuries to Neck

- Abrasions/claw marks (self-inflicted)
- Pressure erythema
- Contusions, including finger pad contusions
- Only about half of strangulation victims have visible injury\*

---

---

---

---

---

---

---

Forensic Healthcare Online

### Visible Injuries to Other Areas

- Contusions behind ears, jaw line, submandibular area
- Tongue injury, including edema and bite wounds (from victim)
- Chin abrasions: protective mechanism causes injury as victim tries to protect neck by bringing chin to chest

---

---

---

---

---

---

---

Forensic Healthcare Online

### Ligature Marks

- Presence should increase suspicion of hyoid bone fracture
- May resemble natural folds of neck
- Presence of jewelry can cause ligature-type marks, even when manual strangulation was sole mechanism of injury

---

---

---

---

---

---

---

Forensic Healthcare Online

### Petechiae

- Burst capillaries occurring at or above the point of pressure
- May be found under and on eyelids, periorbital areas, face, scalp, and neck; also look at lower lip and hairline

---

---


---

---

---

---

---

 Forensic Healthcare Online

### Petechiae

- HOWEVER, it's a non-specific finding which can be caused from asphyxia of any type:
  - Hanging
  - Drowning
  - Sudden infant death syndrome (SIDS)
  - Aspiration of gastric contents
  - Profound depressant drug intoxication
    - Lack of petechiae does not disprove strangulation

---

---


---

---

---

---

---

 Forensic Healthcare Online

### Subconjunctival Hemorrhage

- May be to entirety of conjunctiva, or isolated spot
- Particularly common with repeated pattern of pressure and release

---

---


---

---

---

---

---

 Forensic Healthcare Online

### Neurological Findings

- Ptosis
- Facial droop
- Unilateral weakness
- Paralysis
- Loss of sensation

---

---


---

---

---

---

---

 Forensic Healthcare Online

## Neurological Findings

Studies indicate that victims of repeated strangulation have a significant increase in these symptoms (Smith, et al. 2001)

---

---


---

---

---

---

---

 Forensic Healthcare Online

## Psychiatric Symptoms

- Memory loss
- Depression
- Anxiety
- Suicidal ideation
- Post traumatic stress disorder (PTSD) symptoms
- Nightmares (significant increase in patients who have experienced multiple strangulations)

---

---


---

---

---

---

---

 Forensic Healthcare Online

## Medical Evaluation and Documentation

---

---


---

---

---

---

---

 Forensic Healthcare Online

### Evaluation

- Strangulation victims consistently under-evaluated in Emergency Departments
- Lack of visible injury often correlates with lack of thorough evaluation
- Patients may frequently be dismissed as hysterical, emotionally labile, intoxicated, exaggerating assault details

---

---


---

---

---

---

---

 Forensic Healthcare Online

### Evaluation

Existing symptoms, such as hyperventilation and agitation easily written off as patient drama rather than seen as a logical response to a terrifying and hypoxic event

---

---


---

---

---

---

---

 Forensic Healthcare Online

### Evaluation

- Should be dependent upon signs and symptoms displayed
- Patients with more significant findings, such as dyspnea, visible neck lesions, behavioral, or neurologic changes should have more in-depth studies

---

---

---


---

---

---

---



 Forensic Healthcare Online

### Experts

- Any healthcare provider may be a potential strangulation expert assuming appropriate education and experience.
- Need to look at more than degrees and specialty to evaluate actual expertise.

---

---


---

---

---

---

---

 Forensic Healthcare Online

### Experts

- During the investigation, an expert may be able to help you identify subtle signs and symptoms of strangulation injury.
- At trial, an expert can help educate panel members about lack of visible injury and discuss lethality of the mechanism of injury.

---

---


---

---

---

---

---

 Forensic Healthcare Online

### Direct Exam

- 3 critical areas to include:
  - Terminology
  - Expert's specific experience with strangulation
  - Clinical picture of strangulation

---

---


---

---

---

---

---

 Forensic Healthcare Online

## Defense Tactics

- No injury means no strangulation
- Consensual sex play
- Victim was actually aggressor and was out of control
- Combatives (to counter agg charge or attempt murder)

---

---

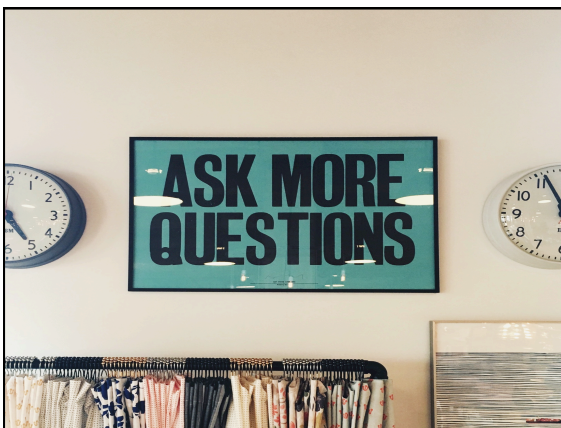---

---

---

---

---



---

---

---

---

---

---

---



---

---

---

---

---

---

---